

Etiology and Treatment of Congenital Festoons

Mokhtar Asaadi

Aesthetic Plastic Surgery

ISSN 0364-216X

Aesth Plast Surg

DOI 10.1007/s00266-018-1129-7



Your article is protected by copyright and all rights are held exclusively by Springer Science +Business Media, LLC, part of Springer Nature and International Society of Aesthetic Plastic Surgery. This e-offprint is for personal use only and shall not be self-archived in electronic repositories. If you wish to self-archive your article, please use the accepted manuscript version for posting on your own website. You may further deposit the accepted manuscript version in any repository, provided it is only made publicly available 12 months after official publication or later and provided acknowledgement is given to the original source of publication and a link is inserted to the published article on Springer's website. The link must be accompanied by the following text: "The final publication is available at link.springer.com".

Etiology and Treatment of Congenital Festoons

Mokhtar Asaadi¹ 



Received: 20 December 2017 / Accepted: 15 March 2018

© Springer Science+Business Media, LLC, part of Springer Nature and International Society of Aesthetic Plastic Surgery 2018

Abstract

Background Festoons and malar bags present a particular challenge to the plastic surgeon and commonly persist after the traditional lower blepharoplasty. They are more common than we think and a trained eye will be able to recognize them. Lower blepharoplasty in these patients requires addressing the lid-cheek junction and midcheek using additional techniques such as orbicularis retaining ligament (ORL) and zygomaticocutaneous ligament (ZCL) release, midface lift, microsuction, or even direct excision (Kpodzo et al. in *Aesthet Surg J* 34(2):235–248, 2014; Goldberg et al. in *Plast Reconstr Surg* 115(5):1395–1402, 2005; Mendelson et al. in *Plast Reconstr Surg* 110(3):885–896, 2002). The goal in these patients is to restore a smooth contour from the lower eyelid to the cheek. The review of literature shows the need for more than one surgery for treatment of the festoons (Furnas in *Plast Reconstr Surg* 61(4):540–546, 1978). One of the reasons WHY these cases are so challenging is that the festoons tend to persist even after surgical treatment. As Furnas said, “Malar mounds have acquired some notoriety for their persistence in the face of surgical efforts to remove them” (Furnas in *Clin Plast Surg* 20(2):367–385, 1993). This could be due to different etiology between acquired and congenital festoons. There are currently no cases of congenital festoons described in the literature. In the last 10 years, we have treated a total of 59 patients with festoons or malar mounds. We used the terminology of

festoon for acquired cases and malar mound for congenital ones (Kpodzo et al. 2014). We were successful with treating 56 patients who developed acquired festoons later on in life; however, three cases required an additional treatment to improve residual puffiness that they had after the first operation. From the above findings, we hypothesized that there should be something common in patients with congenital festoons or malar mounds which are different from acquired festoons. All of these three patients had one thing in common, and that was a history of puffiness of the prezygomatic space since childhood. Each of these patients expressed that these conditions have been present since a young age but became worse with aging over time. To date, there are no descriptions of the cause or treatment for congenital festoons. Here, we present the first case series of three patients with congenital festoons. We discuss the possible etiology of congenital festoons, the physical exam, and the surgical approaches.

Methods We performed a retrospective review of 59 patients who had surgical correction of festoons in the past 10 years, three of which were presented since childhood. In this paper, we will discuss the pathophysiology and the surgical treatments for congenital festoons. Only patients with festoons present since birth were included. The first two cases were treated with a subciliary blepharoplasty with release of the orbicularis retaining and zygomaticocutaneous ligaments and midface lift with canthopexy and orbicularis muscle suspension. The third case had a subciliary lower blepharoplasty approach, skin, and muscle flap and direct excision of the fat through the orbicularis from the subcutaneous space. In addition, each patient required further treatments to address supra-orbicularis fat by various methods.

Results All patients with acquired festoons had successful results with one operation by subciliary skin muscle flap,

✉ Mokhtar Asaadi
mokhtarasaadi@gmail.com

¹ Department of Plastic and Reconstructive Surgery, Saint Barnabas Medical Center, 94 Old Short Hills Rd, Livingston, NJ 07039, USA

release of the ORL and ZCL, midface lift, and muscle suspension. All three patients with congenital festoons had residual puffiness that required surgical and non-surgical treatments. There were no complications. Our first case required three surgical treatments for complete correction. The second and third cases required Kybella injections after their initial surgical treatments. The specimen of the first patient, Fig. 10, who had direct excision, showed localized fat collection immediately under the skin and above the orbicularis oculi muscle.

Conclusions Correction of congenital festoons or malar mounds requires a combination of subciliary lower blepharoplasty with skin muscle flap, midface lift, and orbicularis muscle suspension, as well as addressing the supra-orbicularis fat via direct excision, off-label Kybella injection or liposuction.

Level of Evidence IV This journal requires that authors assign a level of evidence to each article. For a full description of these Evidence-Based Medicine ratings, please refer to the Table of Contents or the online Instructions to Authors www.springer.com/00266.

Keywords Congenital festoons · Acquired festoons · Malar mound · Kybella · Malar edema

Case 1

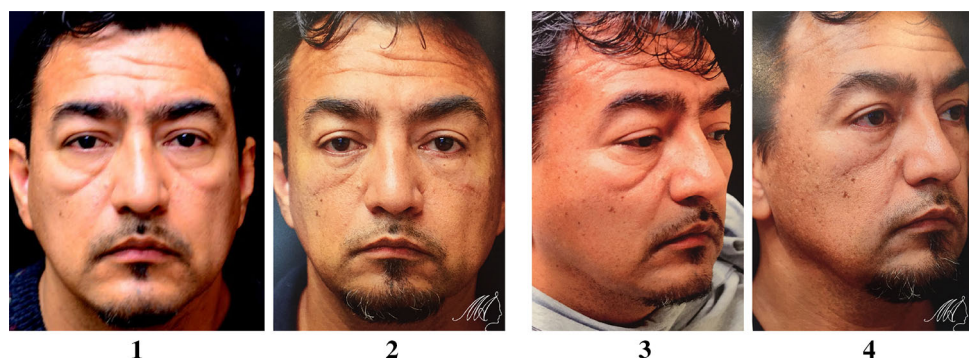The first patient was a 44-year-old male upon his initial visit. He presented with severe bilateral congenital festoons present since birth, as well as bilateral tear trough deformity and lower eyelid fat herniation (Figs. 1, 3, 5). Correction of his congenital festoons required three surgeries, separated by 6 months each. In October of 2012, he underwent bilateral upper and lower blepharoplasty, septal reset, canthopexy, orbicularis muscle suspension, correction of the festoon, temporary tarsorrhaphy, temporal lift, and rhinoplasty.

The surgery was done under general anesthesia as an outpatient. Subciliary lower blepharoplasty with a skin and

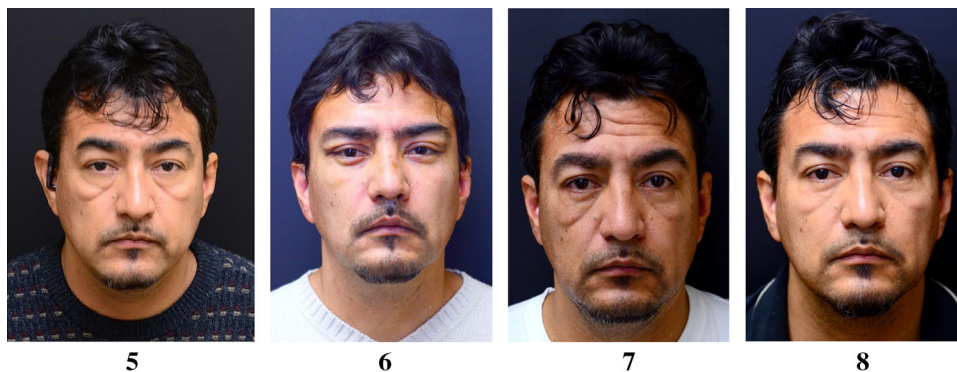muscle flap was done. The tarsal orbicularis muscle was preserved in the lower eyelids. The skin muscle flap was raised from lateral to medial direction by Stevens scissors. The orbicularis retaining ligament was released by blunt dissection. The medial origin of the orbital orbicularis oculi muscle from the maxilla was not released. Zygomatico-cutaneous ligament was released by electrocautery. The arcus marginalis was open along the inferior orbital rim. A small amount of fat excision was done. Septal reset was done by suturing the septum to the inferior orbital rim with continuous 6/0 clear nylon suture. A corneal shield protected the eye and Frost suture was 4/0 silk on the lower lid margin, keeping the lower eyelid in an upward traction during the septal reset. We routinely remove the lateral fat pocket of the lower eyelid through a small opening on the orbital septum in every case. This opening is left open; and after completion of the septal reset, it allows access to any excess fat of the lower eyelid that might need to be removed. Canthopexy was done with a 5/0 PDS suture (polydioxanone), which is a monofilament synthetic absorbable suture on a P-2 needle (Ethicon, Somerville, NJ) by suturing the inferior retinaculum of the lower lids to the inner aspect of the superior orbital rim at the level of the Whitnall's tubercle and Eisler's fatpad, which corresponds to the midpupillary line. Orbicularis muscle suspension was done by separating the skin from the muscle on the lateral lower corner of the lower eyelid and suspending it to the temporal fascia, lateral to the lateral canthus with 5/0 VICRYL (polyglactin suture 910), which is a synthetic absorbable braided suture (Ethicon, Somerville, NJ). Conservative excision of the skin was done on the lateral corner of the incision. No skin was removed medial to the pupil in the subciliary area. Temporary tarsorrhaphy with 6/0 plain fast-absorbing catgut suture was done at the end of the procedure as a preventive measure for development of postoperative chemosis.

This surgery provided moderate correction of the congenital festoons (Fig. 7), but he had residual malar bags that persisted and failed to resolve at 6 months after surgery. In July of 2013, he underwent bilateral revision lower

Figs. 1–4 Before initial surgery and after final surgery



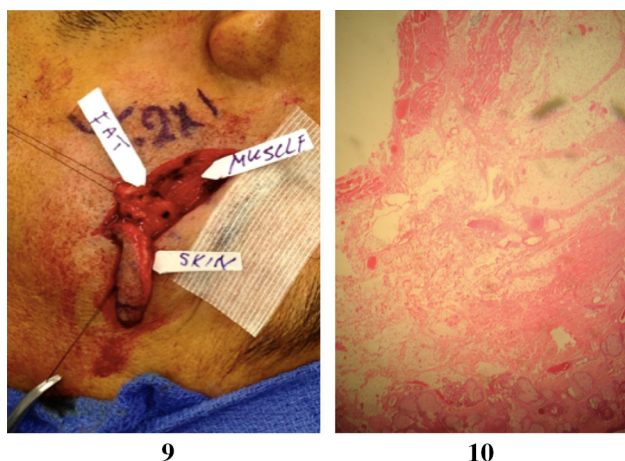
Figs. 5–8 **5** Preop first surgery 9/20/12. **6** 13 day postop first surgery 10/16/12. **7** Preop before second surgery 6/20/13. **8** Preop before third surgery 12/12/13



blepharoplasty with creation of a skin-only flap superficial to the orbicularis, with excision of supra-orbicularis fat in the prezygomatic area. This provided additional correction of the malar bags (Fig. 8); however, full correction required a third surgery, performed in December of 2013 to directly excise the skin and supra-orbicularis fat (Figs. 9, 10).

He achieved full correction of his congenital festoons but has a permanent scar at the site of the excision. In addition, he has a strong history of allergies, especially to food with frequent swelling of the lower eyelids and periorbital area. We are treating him with Singulair (montelukast sodium), 10 mg once a day. The patient is happy with the overall result of the procedure and had no major complications (Figs. 2, 4).

On a separate note, multiple family members of this patient also have congenital festoons, including his 27-year-old son, his 4-year-old grandson, and his 2-day-old granddaughter (Figs. 11–13).



Figs. 9, 10 **9** Direct surgical excision showing fat under the skin and over the orbicularis muscle. **10** Pathology of the cross section of the specimen showing fat under the skin over the orbicularis oculi muscle

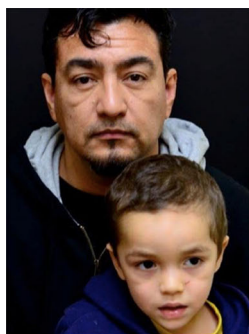Case 2

The second case is a 50-year-old female who presented with bilateral congenital festoons present since birth (Figs. 14, 15). In June of 2016, she underwent bilateral lower blepharoplasty through a subciliary incision with preservation of the tarsal orbicularis. The skin and muscle flap was raised. The orbicularis retaining ligament and zygomaticocutaneous ligament were released. Supra-periosteal dissection of the midface was done under direct visualization to the level of the nostrils. A septal window was used for aggressive excision of the lateral fat pocket of the lower eyelids. Septal reset with fat transposition was done with 6/0 clear nylon suture; canthopexy was carried out with 5/0 PDS suture on a P-2 needle (Ethicon, Somerville, NJ). Orbicularis myotomy and suspension was done to the temporal fascia with 5/0 VICRYL (polyglactin suture 910) (Ethicon, Somerville, NJ). Conservative excision of the lower eyelid skin was done laterally in a triangular fashion. Again, no skin was removed in the subciliary area, medial to the pupils. Bilateral temporary tarsorrhaphy with 6/0 plain fast-absorbing catgut suture was done (Figs. 16–18). The patient also had bilateral upper blepharoplasty, browpexy, mini abdominoplasty, and excision of a suprapubic scar, and also she had Vaser liposuction of the flanks and trochanteric area.

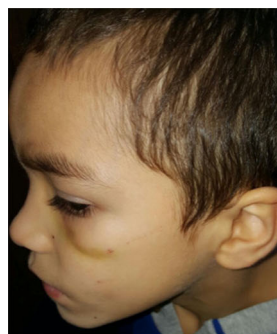She achieved full correction on the left side malar mound postoperatively, but, on the right side, she had some persistent malar fullness (Figs. 19, 21). In November 31, 2016, she had an injection of Kybella (deoxycholic acid ATX-101) (Kythera Biopharmaceuticals, Inc, Westlake Village, CA) to correct the right-sided malar fullness. Kybella (0.1 cc) was injected in two spots on the right malar fullness. Again, on December 8, 2016, she had 0.15 cc of Kybella injected in two spots over the right prezygomatic fullness.

Figures 20, 22 show the patient 9 months after her initial surgery.

Figs. 11–13 11 Patient with grandson. 12 Grandson, 4 years old. 13 Patient's son with granddaughter



11



12



13



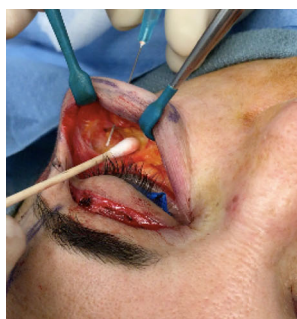14



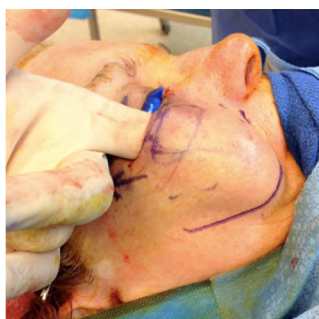15

Figs. 14, 15 Childhood photos of Case 2

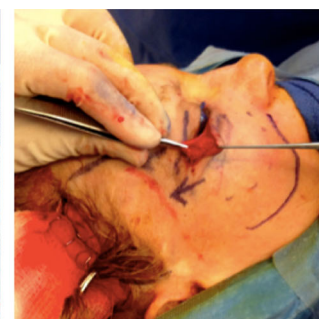Figs. 16–18 16 Needle through the skin shows the location of the zygomaticocutaneous ligament of the left lower eyelid. 17 Supraperiosteal dissection for midface lift. 18 Orbicularis muscle separated from skin muscle flap ready for myotomy and suspension



16

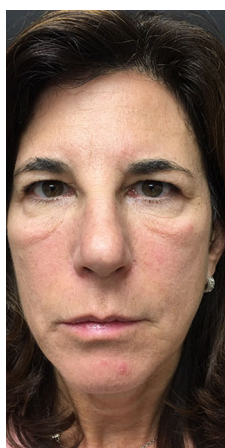

17

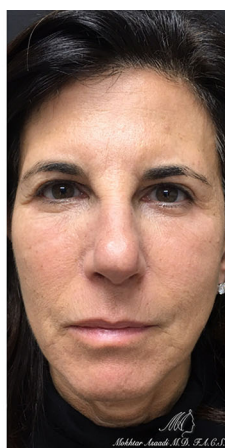

18

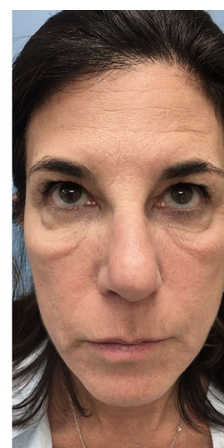Figs. 19–22 19 and 21 Preop of Case 2. 20 and 22 Postop of Case 2 (9 months postop)



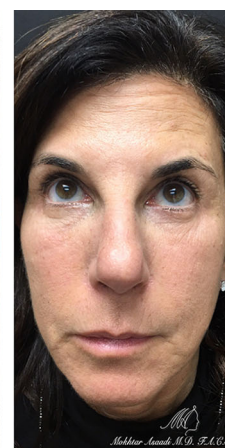19



20



21



22

Figure 23 shows the initial photograph of the second patient before any surgical treatment. Figure 24 shows patient after 1 year postop.

Case 3

The third case is a 30-year-old female who presented with bilateral congenital festoons present since birth (Fig. 25). A Botox test was done during the preoperative evaluation and there was no change in the festoon indicating no



Figs. 23, 24 23 Case 2 Preop. 24 Case 2, 1 year postop



Fig. 25 Childhood picture of Case 3

orbicularis muscle laxity as a primary cause of the festoon. She underwent bilateral lower eyelid surgery on 12/1/2014 in which a skin muscle flap was raised through a subciliary approach. The tarsal orbicularis was preserved along the lid margin. The dissection was continued deep to the orbicularis with release of the ORL, and supra-orbicularis fat was removed in the prezygomatic area by spreading through the orbicularis fibers in this region, under direct vision (Figs. 26, 27).

Figures 28 and 29 shows the initial photograph of the third patient before any surgical treatment as well. She achieved partial correction of her congenital festoons and underwent Kybella (deoxycholic acid) injection to her malar fullness bilaterally in May 2017 (Fig. 30). Kybella

(0.1 cc) (deoxycholic acid) was injected on each side. Although the malar fullness subsided, still she has a linear mark of the zygomaticocutaneous ligament on the left side. The patient is very happy with the results of her right malar mound. Figures 31 and 32 shows patient, 4 years, 2 months post-op, and still with line at the sight of the previous malar mound.

Discussion

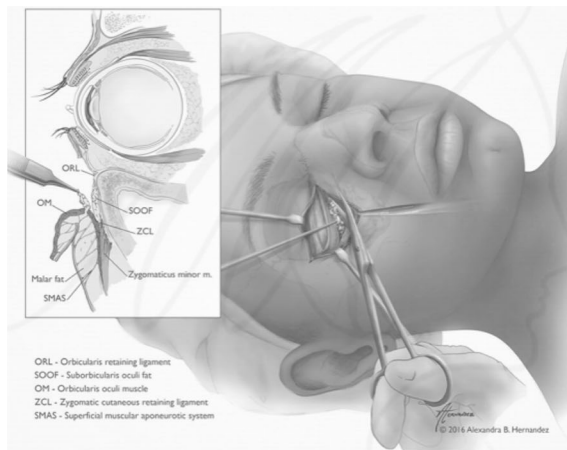
Furnas was first to describe the anatomic basis of festoons as well as a comprehensive approach to treating these conditions [1]. Festoons are thought to be caused by laxity in both the skin and orbicularis muscle of the lower eyelid, which allows descent of the suborbicularis oculi fat and overlying skin. Kpodzo et al. described festoons as “cascading hammocks of lax skin and orbicularis muscle that hang between the medial and lateral canthi and may or may not contain herniated fat.” Festoons are normally located within the prezygomatic space, which is bound by the ORL (orbicularis retaining ligament) superiorly and ZCL (zygomaticocutaneous ligament) inferiorly [2, 3].

The anatomic basis of congenital festoons seems to be different from acquired festoons as previously described in the literature [4]. Congenital festoons seem to consistently involve supra-orbicularis fat in the prezygomatic space. In the first case described here, we encountered a significant collection of subcutaneous fat superficial to the orbicularis that required treatment to correct the congenital festoon. The severity of the festoons is variable in different patients from mild to moderate and severe.

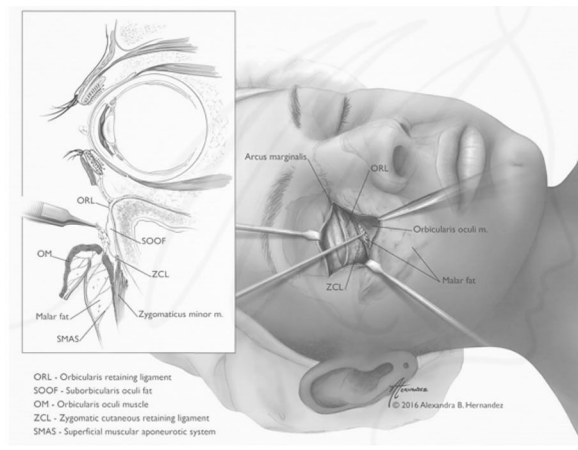
Below, we discuss the difference between acquired festoons and congenital festoons.

The history of patients presenting with festoons and malar bags is extremely important. The majority of the patients with acquired festoons give a history of having puffiness and bags between the lower eyelids and midface. This puffiness started as they aged and was not present when they were young. A small group of patients with malar bags and puffiness give a history of always having puffiness below the lower eyelids and above the midface in all their lives. They have a history of puffiness since childhood that became worse by aging. They usually have a family member with the same findings.

The pathophysiology of these two groups of patients is different. The first group developed festoons as part of aging and have laxity of the orbicularis oculi muscle with or without excess skin [5]. In this group of patients, clinical evaluation is important. One simple test is by forceful closure of the eye. In the case of acquired festoons, forceful closure of the eyes improves the festoon because of tightening of the orbicularis muscle. In the case of congenital



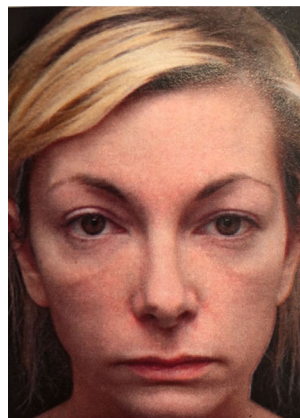
26



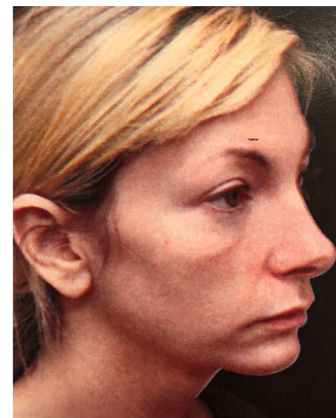27

Figs. 26, 27 Artistic illustration of excision of the subcutaneous fat under the surface of the orbicularis after raising the skin muscle flap

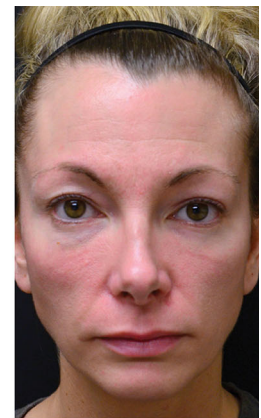
Figs. 28–30 28, 29 Case 3
Preop. 30 Case 3, 29 months
postop before Kybella injection



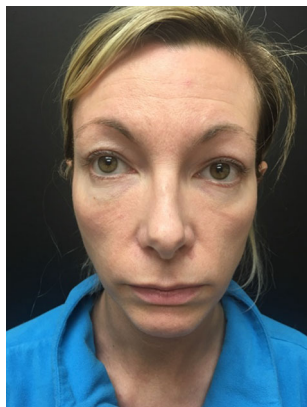28



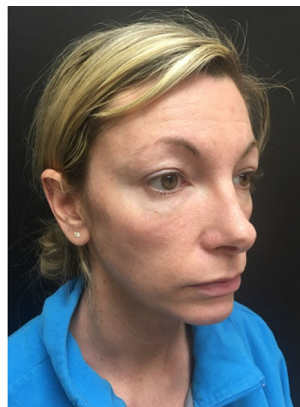29



30



31



32

Figs. 31, 32 4 years, 2 months postop

festoon, forceful closure of the eye displaces the malar mound upward but does not completely get rid of the prezygomatic fullness.

Another helpful test is by pulling the lateral part of the lower eyelids upward and laterally with the examiners index finger (LATERAL PULL TEST). Because the primary cause of the festoons in acquired cases is laxity of the orbicularis oculi muscle, this test improves the puffiness.

In the second group of patients with malar mounds or congenital festoons, the lateral pull test will improve the malar mounds, but they still have residual fullness that does not go away, because of the subcutaneous location of localized fat over the orbital orbicularis oculi muscle at the prezygomatic space.

Another test can be done to differentiate acquired from congenital festoons. The test is called the Botox test. Goldman also reported the same findings [6]. Injection of Botox (onabotulinumtoxinA), a highly purified preparation of a toxin produced by *Clostridium botulinum*, blocks signals from the nerves to the muscles that make the wrinkles relax and soften.

Botox injection to crows' feet will cause temporary paralysis of the orbicularis oculi muscle. In patients with

acquired festoons, because the primary pathophysiology is laxity of the orbicularis oculi muscles, the Botox test will make the festoons become worse.

This is a positive test in patients with acquired festoons.

In patients with congenital festoons, Botox injection does not change the appearance of the malar mounds, because the primary pathophysiology is not weakness and laxity of the orbicularis oculi muscles and is localized subcutaneous fat collection over the orbital orbicularis oculi muscles in the prezygomatic space. This is called a negative Botox Test.

The majority of the patients who present with festoons and malar mounds give a history of changes of the severity of their puffiness. In other words, certain environmental conditions like allergies and foods affect the severity of their conditions.

Therefore, the proper classification of festoons should be as follows, as suggested by Kpodzo [2]:

1. Congenital bags, called MALAR MOUNDS;
2. Acquired bags, called FESTOONS;
3. Medical bags, called MALAR EDEMA;
4. Combination of above conditions.

The anatomy of the lower eyelids and periorbital area can help in understanding the pathophysiology of this “mysterious” part of the face. The malar fat, which is also called a medial subcutaneous fat pad, is located in the prezygomatic area and covers the orbital portion of the orbicularis oculi muscle, but the palpebral orbicularis is not covered by the malar fat pad. The malar fat is superficial to the SMAS. The deep sub orbicularis oculi fat (SOOF) lies below the SMAS and the orbicularis oculi. The orbicularis–facial fat complex is invested with the SMAS [7]. The malar fat pad is attached to the orbicularis muscle and SMAS, and therefore, the orbicularis muscle suspension lifts the malar fat and improves the malar fat in congenital festoons [8, 9].

In our first case, this localized fat could be seen immediately under the skin and on the top of orbicularis muscle at the time of direct excision (Fig. 9).

Surek also describes a superficial pad overlying the prezygomatic space [10].

The reasons for failures in the first and second procedures in our first case were unsuccessful removal of the localized subcutaneous fat which was the main pathophysiology of this congenital festoon patient. In our first procedure, we attempted to correct the malar mounds by the subciliary lower blepharoplasty approach and release of the orbitomalar and zygomaticocutaneous ligaments, mid-face lift, and orbicularis muscle suspension similar to the procedure that we have done in our acquired cases. In addition, we performed postseptal fat excision and

transposition with septal reset for correction of the herniated lower lid fat and nasojugal grooves.

Although the malar puffiness improved immediately after the surgery (Fig. 6), the patient develops fullness of the prezygomatic space after the initial surgical swelling subsided (Fig. 7). In the second procedure, we tried to remove the subcutaneous fat in the prezygomatic space, through the subciliary approach, by raising the skin flap and removing fat from the prezygomatic space superficial to the orbital orbicularis muscle. Although a small amount of fat was removed, the residual remaining fat could not be completely excised because of lack of adequate exposure (Fig. 8). Raising the skin flap through the subciliary approach to the prezygomatic space has the potential problem of skin necrosis of the lower eyelids because of jeopardized circulation to the skin, therefore, is not without potential risks.

The main reason which Kybella was not used as the primary treatment of the congenital festoons is because these patients also may have concomitant laxity of the orbicularis muscle and excess skin that is not going to be corrected by Kybella injection alone. However, in young patients with congenital festoons and good muscle tone and no excess skin, Kybella injection should be the first choice for treatment.

Informed consent should be taken from patients after thorough explanation of the use of Kybella and it should clearly be mentioned that Kybella is used as “OFF LABEL” in this part of the face.

Our first case still has lower lid puffiness and residual nasojugal grooves despite fat transposition and septal rest. This could be because a strong history is of severe allergies to many foods and he is taking medication for allergies that somehow controls his eyelid puffiness. The patient is on Singulair (Montelukast sodium), 10 mg once a day.

KYBELLA (deoxycholic acid) is the first and only FDA-approved injectable treatment to reduce fat under the chin. Deoxycholic acid, also known as cholanoic acid, Kybella, Celluform Plus, Belkyra, and 3 α ,12 α -dihydroxy-3 β -cholanoic acid, is a bile acid. Deoxycholic acid is one of the secondary bile acids, which are metabolic byproducts of intestinal bacteria.

Formula: C₂₄ H₄₀ O₄.

Molar mass: 392.572 g/mol.

Kybella is identical to something your body makes called deoxycholic acid, which helps to absorb fats, the FDA says. Kybella is the synthetic form of deoxycholic acid and it works by destroying fat cells. The shot is an alternative to liposuction or surgery to treat double-chin fat. Injecting Kybella causes fat cells to be destroyed, taking a few weeks for the body to expel the fat.

Excision of the fat through the subciliary approach with a skin flap or skin muscle flap is difficult and might require

an extended incision laterally. Removing the fat through the orbicularis might cause temporary lid retraction and scleral show because of the scarring in the muscle.

To decrease the redundancy of the skin in the lateral corners of the eyes after lower lid midface lift, we have used the following accessory procedures.

Short scar temporal lift, browpey through upper eyelids, temporal/lower lid/midface tunnel, excision of soft tissues, and the orbicularis muscle from the lateral part of the upper eyelid blepharoplasty incision and Botox injection to the lateral tail of the eyebrow help elevate the lateral eyebrows. Almost all of the redundancy of the skin in the lateral canthal area will flatten out in a few weeks. In some cases, it might take 12 weeks and patients should know about a longer recovery time as a trade-off for correction of the festoons.

Chemosis is also more commonly seen when treating festoons and malar bags. Our treatment protocol is topical anti-inflammatory eye drops and short courses of oral anti-inflammatory medications like Medrol Dose pack (methylprednisolone). Comprehensive management for chemosis was described by McCord [11].

We have found that a midface lift alone is often insufficient to correct congenital festoons, without removing the subcutaneous fat. However, resection of subcutaneous fat alone would not be enough either. The midface lift is critical in correction of these congenital festoons by tightening the orbicularis laterally.

All three patients in this series achieved improvement in the appearance of their congenital festoons [12]. Based on our experience with treatment of congenital festoons, we recommend a staged approach to these cases. The initial stage should involve a midface lift as part of the standard blepharoplasty, with release of both the ORL and zygomaticocutaneous ligaments and tightening of the orbicular muscle. As part of the lower blepharoplasty, we do routinely perform conservative triangular skin excision laterally depending on how much excess remains after the midface lift. However, we advise that the skin excision be done with extreme caution, as anything more than conservative excision could result in complications involving lower lid malposition. No skin is removed in the subciliary area medial to the pupil. We strongly believe that postoperative lid retraction and ectropion is due to excess skin excision.

The usual recommend dose for Kybella in the chin area is 0.2 ml per injection site.

In both of our second and third cases, 0.1 ml and in the second treatment for our second patient, 0.15 ml was injected. None of them had any local reactions, no redness, no swelling, but they had localized tenderness and soreness for few days after injection. Results of the treatment are seen after 3–4 weeks.

Kybella (deoxycholic acid) comes in 20 mg/2 ml vials. With 0.2 ml injected per site, ten spots are usually injected in the submental area.

Injection is done with a 1 ml syringe and a 30-gauge needle.

Direct excision [13], laser treatments [14], and superficial liposuction of festoons [15] are other modalities for treatment. Liposuction has a potential problem of creating skin irregularities and laser treatment mostly targets skin rather than the orbicularis muscle laxity or subcutaneous fat collection. Finally, direct excision will leave a permanent scar which is not acceptable, especially in a young patient requesting aesthetic improvement in their face.

The etiology of malar edema, which is mostly triggered by allergies, could be explained on the basis of superficial lymphatics and perilymphatic fat located under the wrinkles, as described by Pessa [16].

Conclusion

The severity of the festoons will determine what surgical procedure should be done.

The first two cases had severe festoons and needed lower blepharoplasty and release of the ORL and ZCL and muscle suspension. They both had elevation of the brows by a temporal lift (first case) and browpey (second case).

The third patient had a mild case of congenital festoons and was treated by fat removal only. All of our acquired festoons were treated by subciliary lower blepharoplasty, release of ligaments, and muscle suspension with or without myotomy. Severe cases had temporal/lower lid/midface tunnel and aggressive temporal lift, just through the lateral lower lid incision.

Congenital festoons are a unique challenge for the plastic surgeon. Correction requires a combination of a midface lift as part of the lower blepharoplasty procedure as well as addressing the supra-orbicularis fat, which has not been known to be associated with acquired festoons. This can be done with direct excision, off-label Kybella injection, or liposuction [17].

Compliance with Ethical Standards

Conflict of interest The author declares that he has no conflict of interest.

References

1. Furnas DW (1978) Festoons of orbicularis muscle as a cause of baggy eyelids. *Plast Reconstr Surg* 61(4):540–546
2. Kpodzo DS, Nahai F, McCord CD (2014) Malar mounds and festoons: review of current management. *Aesthet Surg J* 34(2):235–248

3. Kikkawa DO, Lemke BN, Dortzbach RK (1996) Relations of the superficial musculoaponeurotic system to the orbit and characterization of the orbitomalar ligament. *Ophthalmic Plast Reconstr Surg* 12(2):77–88
4. Goldberg RA, McCann JD, Fiaschetti D, Ben Simon GJ (2005) What causes eyelid bags? Analysis of 114 consecutive patients. *Plast Reconstr Surg* 115(5):1395–1402 (**discussion 1403–4**)
5. Mendelson BC, Muzaffar AR, Adams WP Jr (2002) Surgical anatomy of the midcheek and malar mounds. *Plast Reconstr Surg* 110(3):885–896
6. Goldman MP (2003) Festoon formation after infraorbital botulinum A toxin: a case report. *Dermatol Surg* 29:560–561
7. Zins JE, Hashem AM (2016) Commentary on: SMAS fusion zones determines the subfascial and subcutaneous anatomy of the human face: fascial spaces, fat compartments, and models of facials again. *Aesthet Surg J* 36(5):527–528
8. McCord CD, Codner MA (eds) (2008) *Eyelids and periorbital surgery*. St. Louis, Quality Medical Publishing Inc, p 25
9. Nahai F (ed) (2011) *The art of aesthetic surgery, principles and techniques*, 2nd edn. St. Louis, Quality Medical Publishing, p 1332
10. Surek CC, Beut J, Stephens R, Jelks G, Lamb J (2015) Pertinent anatomy and analysis for midface volumizing procedures. *Plast Reconstr Surg* 135(5):818e–829e
11. McCord CD, Kreymerman P, Nahai F, Walrath JD (2013) Management of the postblepharoplasty chemosis. *Aesthet Surg J* 33(5):654–661
12. Furnas DW (1993) Festoons, mounds, and bags of the eyelids and cheek. *Clin Plast Surg* 20(2):367–385
13. Einan- Lifshitz A, Hartstein ME (2012) Treatment of festoons by direction excision. *Orbit* 31(5):303–306
14. Scheiner AJ, Baker SS, Massry GG et al (eds) (2011) *Laser management of festoons. Masters techniques in blepharoplasty and periorbital rejuvenation*. Springer, New York, pp 211–221
15. Rosenberg GJ (1995) Correction of saddlebag deformity of the lower eyelids by superficial suction lipectomy. *Plast Reconstr Surg* 96:1061–1065
16. Pessa JE, Nquyon H, John GB, Scherer PE (2014) The anatomical basis for wrinkles. *Aesthet Surg J* 34(2):227–234
17. Liapakis IE, Paschalis EI (2012) Liposuction and suspension of the orbicularis oculi for the correction of persistent malar bags: description of technique and report of a case. *Aesthetic Plast Surg* 36(3):546–549